



**PATIENT**

Coco Puffer

**SPECIES**

Feline

**BREED**

DSH

**SEX**

Male Neutered

**AGE**

5 years

**WEIGHT**

10lbs

**INTERPRETED BY**

Maggie Machen Lamy,  
 DVM, DACVIM  
 (Cardiology)

**IMAGING PERFORMED BY**

Meghan Morse LVT,  
 CVT

**HOSPITAL NAME**

All Animal Veterinary  
 Services

**REFERRING VET**

Dr. Acworth

**INVOICE**

45846

**DATE**

11/19/25

**PRESENTING CLINICAL SIGNS**

History: Grade 3/6 heart murmur. Rapid HR. Coughing previously but owner said improved with air purifier.

**ECHOCARDIOGRAM FINDINGS**

2D, m-mode, color flow and doppler imaging is available. The left ventricular wall is normal in dimension. There is a mildly hyperechoic endocardium. The papillary muscles are normal in size. The endocardium appears normal. The left atrium is normal in size. The right atrium is normal in size. The right ventricle appears normal. The mitral valve is normal in structure and mobility. Normal flow through both the RVOT and LVOT. No MR or TR. No AI or PI. No pleural or pericardial effusion seen. No obvious cardiac tumors.

**CARDIAC CHART**

FELINE CARDIAC PARAMETERS	BODY WEIGHT (kg)	HR (BPM)	IVSd (cm) (Moise, Pipers)	LVIDd (cm) (Moise, Pipers)	LVWd (cm) (Moise, Pipers)	FS (%)	EF (%)
NORMAL PARAMETER	-----	150-240	0.35-0.55	<2 (mean 1.5)	3.5-0.55	35-67	80-100
PATIENT	4.5	NM	0.45	1.6	0.44	50	84
FELINE CARDIAC PARAMETERS	LA/AO (Boon)	LA/AO HEART BASE (Swe) (Abbott)	LA 2D short axis Base view (cm) (Abbott)		LVOT VEL (m/s)	RVOT VEL (m/s)	E max (m/s)
NORMAL	<1.5	<1.3	<1.2		<1.6	<1.3	<0.9
PATIENT	NM	1.3	1.3		1.2	1.0	NM

*\*Note: All measurements based upon multi-modal images and methods. An average value is reported.  
 Adapted from June Boon, Veterinary Echocardiography, 1998  
 Abbott J & MacLean H JVIM 2006;20: 111-119, Moise et al. Am J Vet Res 47:1476, 1986. Pipers et al. Am J Vet Res 40:882, 1979.*

**INTERPRETATION OF THE FINDINGS & FURTHER RECOMMENDATIONS**

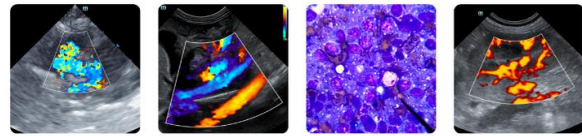
Overtly normal cardiac structure and function. The LV wall thickness is normal and there is no evidence of elevated left atrial pressure. No significant valve leaks are appreciated and flow through the great vessels is normal. These findings would suggest the murmur is likely physiologic in origin.

These findings would certainly suggest a cough in this patient is noncardiogenic in origin. No comment can be made on the HR without an ECG, which may be indicated.

Given these findings, no medications are indicated. It is important to note that phenotypic HCM can develop at any phase of life in cats, particularly in this predisposed breed and periodic screening is ideally recommended.

No cardiac contraindication for general anesthesia at this time.

Recommend recheck echocardiogram in 1 year to assess for development of disease, sooner if clinical signs develop in the interim.



**PATIENT**

Coco Puffer

**SPECIES**

Feline

**BREED**

DSH

**SEX**

Male Neutered

**AGE**

5 years

**WEIGHT**

10lbs

**INTERPRETED BY**

Maggie Machen Lamy,  
DVM, DACVIM  
(Cardiology)

**IMAGING PERFORMED BY**

Meghan Morse LVT,  
CVT

**HOSPITAL NAME**

All Animal Veterinary  
Services

**REFERRING VET**

Dr. Acworth

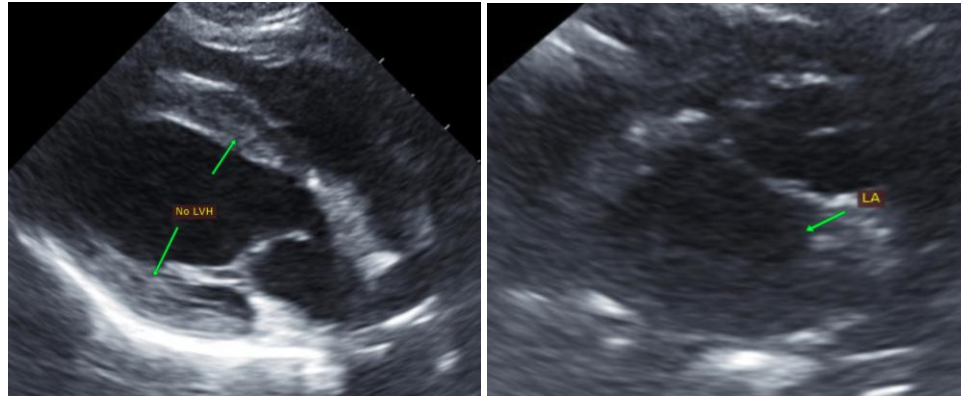
**INVOICE**

45846

**DATE**

11/19/25

**IMAGES**



The information and recommendations provided are based on the images presented by the referring veterinarian. No evaluation can be communicated regarding pathology that was not visible in the image/video clips provided.

Thank you for this referral. This report was generated using transcription software, and minor dictation errors may be present. If the clinical or image interpretation does not parallel your findings or if I can be of any further assistance, please contact me.

**Maggie Machen Lamy, DVM**  
Diplomate of the American College of Veterinary Internal Medicine (Cardiology)  
info@sonopath.com